



Multiple applications using new vascular filters : 500(S), 530D and 550(S)

Dr. Je hyuk Lee

Clinic Director, Dr. Bom Skin & Laser Clinic (Seoul / Korea)

Backgrounds :

Intense Pulsed Light (IPL) has been one of the most popular ways of photo rejuvenation therapies. For aesthetic and therapeutic purposes, pulsed polychromatic light in a broad wavelength spectrum is widely used for improvement of pigmented lesion treatment and skin texture. It is very effective for pigmented lesion, also used for hair removal and vascular lesion treatment. There will be no doubt that IPL has the broad treatment ranges and stabilities for pigmented and vascular lesions for most doctors.

Typical vascular treatments in dermatology are IPL, Pulsed Dye Laser (PDL), 532nm KTP laser, 1064nm Nd:YAG and 755nm Alexandrite. A common characteristic of these light devices is to use the absorption coefficient for hemoglobin.

For vascular lesion treatment, other than IPL should be careful for purpuric reaction. It means IPL has reduced risks of purpura and scar formation hazards. Also if the suitable wavelength laser with proper cooling and parameter setting is used, the side effect of vascular lesion treatment can be prevented dramatically.

The difference between IPL and LASER can be found in the light characteristic. Broad-spectrum of IPL is generated by its polychromatic and non-coherent light. It can be affected by unwanted wavelength reaction without the light controlled. The consensus that vascular lasers such as PDLs are more effective for vascular treatment than IPL seems to be made by each device's wavelength characteristic.

The introduction of a split dual band IPL technology which controls the wavelength spectrum by the short pass filters which are the turning point for the previous

IPL's perception (both wanted and unwanted wavelength ranges emitted together).

Furthermore, a narrow single band with controlling a selectively narrow wavelength can be considered as an alternative treatment to avoid dyschromia, caused by the low fluence Q-switched Nd:YAG Laser toning for melasma treatment.

I do use dual band and narrow single band filter for, benign pigment lesions, flushings and telangiectasia lesions treatment. In this testimonial, the clinical course of "Selective Spectral Stacking technique (SSST)", which can be applied to the multiple applications using cellec v's various filters, will be introduced briefly.

Materials :

Nowadays, IPL system is widely used in clinical practice such as epidermal melanocytic lesions, vascular lesions and photo rejuvenation.

Many discussions and studies have been conducted to determine the most effective IPL filter ranges for various clinical applications.

Jeisys Medical Inc. recently released the upgraded IPL device, cellec v, which has 3 new vascular specialized filters such as 500(S), 550(S) and 530(D) with superior absorption of oxyhemoglobin and deoxyhemoglobin. The previous IPL device, cellec provided 530(S) filter for vascular lesion treatment, but newly upgraded three filters 500(S), 550(S) & 530D are expected to maximize the effects of vascular treatments.

500(S) filter (500~600nm) has a high absorption level for both vessels and melanin, therefore it could be used for patients with skin types I and II. Due to its high absorption spectrum (542 and 570nm) for

oxyhemoglobin, it is effective to treat small superficial vascular lesions within penetration depth 0.5~1.0mm.

550(S) filter (550~650nm) with the high absorption spectrum (570nm) is effective for oxyhemoglobin (predominantly found in clinically red lesions). As its wavelength range has relatively lower melanin absorption than 500(S), it can be used in the patients with vascular lesions in skin types III-IV.

Specialized dual band 530(D) filter emits simultaneously both short wavelengths (530~650nm) and long wavelengths (900nm~).

Short wavelengths (530~650nm) are extremely effective for superficial vascular lesions, having high absorption of oxyhemoglobin and deoxyhemoglobin with shallow penetration depth. Long wavelengths (900nm~) can provide thermodynamic heating to deep vessels and destroy them, although they have low absorption in vascular lesions.

This dual band filter, 530(D) blinds the wavelengths range (650~900nm) to decrease the absorption of melanin and provide a much safer treatment with contact cooling.

Patients and Methods

Patients :

Those who have benign pigmented lesions excluding melasma and flushing in patients were treated.

40 patients (31 women, 9 men; mean age 35.4, range 23-62; Fitzpatrick skin type 3.1, range I – V) with lentigine, ADM (Acquired Dermal Melanosis), telangiectasia and rosacea were treated with an average number of treatment sessions of one to three (a mean session 1.35).

The trial was performed on 29 cases of telangiectasia, 23 cases of rosacea, 32 cases of lentigine, and 9 cases of ADM (Acquired Dermal Melanosis).

Methods :

To minimize post-inflammatory hyper/hypopigmentation, various celled v filters were operated depends on patients' skin types with pigmented lesions and flushing. Patients with Fitzpatrick skin type 1-2 were treated by 500(S), 530(S), 530(D) and 550(S) filters. Patients with Fitzpatrick type 3 were treated by 530(S) and 550(S) filters. Patients with Fitzpatrick type 4 were

treated by mainly 550(S) filter, and 530(D) filter only for telangiectasia treatment. Patients with facial flushing in Fitzpatrick type 5 were multiply treated by 550(S). Most patients with pigmented lesions were treated by 560, 590, 640, and 700nm filters. Some case of rosacea and telangiectasia were treated by 560nm filter in the lentigine mode.

Patients with lentigine were received the treatment using 560nm, 590nm and 640nm IPL filters (single to double pulse 2.4 to 4.4ms).

Patients with telangiectasia were treated by short pass filters according to their skin types (single to multiple pulse mode, 2.8~10.0ms pulse duration, 20ms pulse delay).

Pre-and postoperative evaluation of patients were based on the photographs taken with digital camera (Olympus EM-1) in a photo booth, preventing external light and patients' score in SVSS, Subjective Visual Scale Score(-2 to +2).

Results :

In Table 1-1, 30 patients with facial flushing were treated. Among them, 10 patients with telangiectasia showed SVSS +2 improvements. Additionally, three cases of ADM, eight cases of lentigines and eight cases of rosacea were improved too. 14 patients with telangiectasia and 11 patients with lentigines showed SVSS +1 improvement. 8 patients with telangiectasia and 3 patients with lentigines showed no improvement.

In Table 1-2, 10 patients without facial flushing were treated. Among them, 6 patients with lentigines showed SVSS +2 improvements. 2 patients with lentigines showed SVSS +1 improvement. 2 patients with lentigines showed no improvement.

There were ADM cases in all Tables (Table 1-1, 1-2, 2-1 and 2-2), but none of them showed exacerbation.

■ Table 1-1: 30 Patients with facial flushing

Skin lesion SVSS Improvement	Target: Telangiectasia (cases)	Additional effect		
		Lentigine (cases)	Rosacea (cases)	ADM (cases)
Improvement +2	10	8	8	3
Improvement +1	14	11	11	3
Improvement 0	6	3	4	1

■ Table 1-2: 10 Patients without facial flushing

Skin lesion SVSS Improvement	Target: Lentigine (cases)	Additional effect
		ADM (cases)
Improvement +2	6	0
Improvement +1	2	1
Improvement 0	2	1

■ Table 2-1: 32 Patients with pigmented lesions

Skin lesion SVSS Improvement	Target: Lentigine (cases)	Additional effect		
		Telangiectasia (cases)	Rosacea (cases)	ADM (cases)
Improvement +2	14	8	6	3
Improvement +1	13	10	7	4
Improvement 0	5	3	1	2

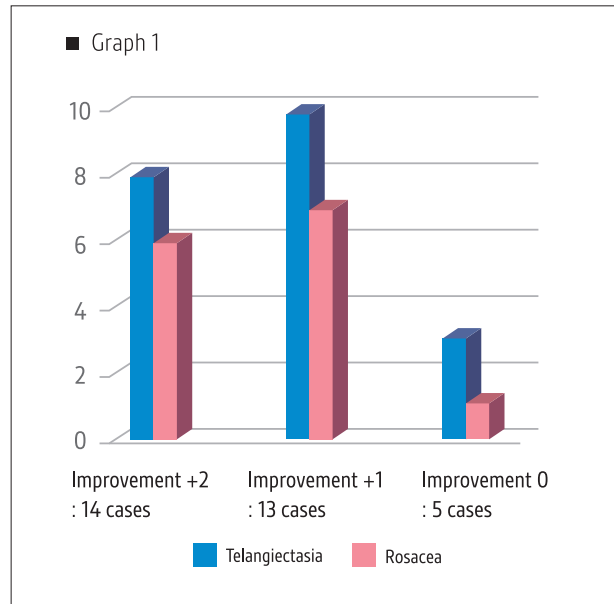
■ Table 2-2: 8 Patients without pigmented lesions

Skin lesion SVSS Improvement	Target: Telangiectasia (cases)	Additional effect
		Rosacea (cases)
Improvement +2	2	2
Improvement +1	3	3
Improvement 0	3	3

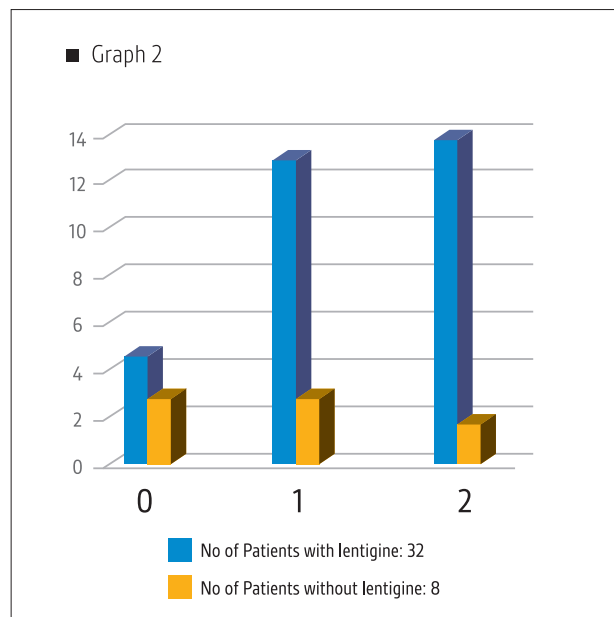
Patients with pigmented lesion showed more improvement rate than facial flushing cases after cellec v treatment (84.4% vs. 80%). Among them, 6 of 10 patients (60%) with lentigine showed SVSS + 2 improvements in Table 1-2.

Otherwise, patients with facial flushing and lentigine showed relatively less SVSS + 2 improvements rates (33%) in Table 1-1.

The treatment satisfaction of patients with facial flushing (only telangiectasia) was higher, and the patient satisfaction treating with facial flushing and rosacea was relatively low in Graph 1.



Generally, the improvement rate of cellec v treatment in pigmented lesions was higher than facial flushing cases.



The satisfaction rates were higher than patients with lentigine. It is consistent with the characteristics of IPL, which improves the various properties of the skin. Patients' assessments of the treatment improvement were as follows;

- "The skin tone has brightened",
- "Skin texture improved"
- "Makeup looks good",
- "Reduced flushing and warmth",

"Pigmented lesions are reduced.", and etc.
Some patients who had experienced laser toning told IPL treatment was less painful than laser toning.

Conclusion & Clinical experience

The Selective Spectral Stacking technique of cellec v is effective in treating pigmentation and facial flushing. Additionally, laser toning and dermal resurfacing can be performed together, so the versatility of cellec v is very wide in the aesthetic treatment field.

Based on trials of 40 patients in this study, cellec v can be defined as "a rejuvenation & treatment procedure" which improves the pigmented lesion, skin texture, and flushing together at a low cost to the patient.

Although the pigmented lesion was mainly focused on the epidermal pigment (lentigine), the secondary improvement effect of enhanced dermal remodeling increased the patient satisfaction.

As the major mechanism in rosacea exacerbation is induced by immunological factors and external stimulants, it is presumed that improvement rate of rosacea is less than telangiectasia treatment.

Clinical trial results can be improved, if topical or oral medication is used together.

cellec v is an attractive device to the practitioner because it guarantees high treatment compliance and procedural stability in patient by not taking the long operation time.

As a sole cellec v treatment can be hard to remove lentigine completely, it is recommendable to conduct the combination therapy of cellec v and Q-switched Nd:YAG Laser (QSNL).

Although there are an argument that IPL is less effective in vascular lesion treatment, based on my experience cellec v can be effective in the complete removal of an extended single vessel.

In addition, I would like to recommend cellec v as a first light therapy for rosacea and diffuse erythema treatment without hesitation.

Discussion

The Selective Spectral Stacking technique is designed to achieve both photorejuvenation and selective wavelength's effect, which are generated by the

previous IPL's wide wavelength band while using 2-3 passes of selective wavelength. Since the parameter of the 530(D) filter has not been fully understood, presumably a useful parameter guideline for vascular applications can be provided in the near future. To minimize dyspigmentation and post-inflammatory hyper/hypopigmentation when using 530(D) filter in Asian skin, its parameter is being verifying.

In the case of the skin characteristics with the high melanin index, the application of the 530nm dual band filter, which is effective for vascular treatment, was carefully considered. Probably, it seems that this consideration made the higher improvement rate of pigmented lesions than vascular treatment. If the examination of 530(D) filter parameter and clinical experience are completed, the improvement rates of both pigmented and vascular lesions will be shown almost equally.

As patients with rosacea were in erythematotelangiectatic rosacea (ETR) type, cellec v treatment effectiveness of other types of rosacea could not be verified.

The various wavelength characteristics of IPL have made an obstacle to become a mainstream device with light therapy in the treatment of melasma. But it is often seen to use the multi band -laser therapeutic strategy using the various wavelengths for melasma treatment. In other words, it contradicts the assertion that IPL should be excluded in the melasma treatment because of its polychromaticity characteristics.

If the power density of IPL can be equivalent to the long pulsed laser in more selectively narrow band or triple narrow band, it could be expected to increase the reliability of IPL treatment as a multiplatform light device. For example, imagine that if IPL can have enough output power and more selective band, it can also achieve more advanced treatment outcome in vascular and melasma lesions using only 1-2 passes.